

An Outbreak of *Phialemonium* Infective Endocarditis Linked to Intracavernous Penile Injections for the Treatment of Impotence

Jacob Strahilevitz,^{1,a} Galia Rahav,¹ Hans-Josef Schroers,⁹ Richard C. Summerbell,⁹ Ziva Amitai,⁷ Anna Goldschmied-Reouven,² Ethan Rubinstein,¹ Yvonne Schwammenthal,³ Micha S. Feinberg,⁵ Yarden Siegman-Igra,⁶ Edna Bash,⁶ Itzhack Polacheck,⁸ Adrian Zelazny,² Susan J. Howard,¹⁰ Pnina Cibotaro,¹ Ora Shovman,⁴ and Nathan Keller²

¹Infectious Diseases Unit, ²Laboratory of Microbiology, Departments of ³Neurology and ⁴Medicine B, and ⁵Heart Institute, Sheba Medical Center, and ⁶Infectious Disease Unit and Microbiology Laboratory, Sourasky Medical Center, Sheba Medical Center, Sackler School of Medicine, Tel-Aviv University, and ⁷District Health Office, Ministry of Health, Tel Aviv, ⁸Department of Clinical Microbiology and Infectious Diseases, Hadassah-Hebrew University Medical Center, Jerusalem, Israel; ⁹CBS Fungal Biodiversity Centre, Utrecht, The Netherlands; and ¹⁰Regional Mycology Reference Centre, Hope Hospital, Salford, United Kingdom

Background. In March 2002, a patient in Tel Aviv, Israel, died of endocarditis caused by *Phialemonium curvatum*. As part of his therapy for erectile dysfunction, the patient had been trained to self-inject a compound of vasoactive drugs provided by an impotence clinic into his penile corpus cavernosus.

Methods. We identified the used prefilled syringes as the source of his infection. Similar cases were investigated as a putative outbreak of *P. curvatum* invasive disease among customers of this impotence clinic. *P. curvatum* isolates, cultured from samples obtained from the patients and from prefilled syringes, were compared by DNA sequencing of the nuclear ribosomal internal transcribed spacer.

Results. We identified 2 additional customers at the impotence clinic who had *P. curvatum* endocarditis. In addition, cultures of unused, prefilled syringes and bottles provided by the same clinic to 5 asymptomatic customers tested positive for pathogenic molds (*P. curvatum* in 4 cases and *Paecilomyces lilacinus* in 1). All *P. curvatum* isolates were of a single genetic type that is known only from this outbreak but is closely related to 3 other *P. curvatum* genotypes associated with pathogenicity in humans.

Conclusions. *P. curvatum* is an emerging pathogen that can be readily isolated from blood. We identified an outbreak of *P. curvatum* endocarditis among men who had erectile dysfunction treated by intracavernous penile injections from contaminated prefilled syringes.

Erectile dysfunction is a common problem, affecting up to 52% of men aged 40–70 years [1]. The current availability of an effective and safe oral therapy for erectile dysfunction, in conjunction with the tremendous media interest in the condition, has resulted in an increasing number of men seeking help for this condition. Intracavernosal injection of prostaglandin E1 or vasoactive drug mixtures has been a popular remedy for

erectile dysfunction and is a reliable and safe option, with an erectogenic effect generally superior to that obtained with sildenafil [2].

Phialemonium species are saprotrophic molds that have rarely been identified as causing invasive disease [3]. In March 2002, a patient in Israel died of *Phialemonium curvatum* endocarditis. The source of his infection was contaminated intracavernous penile injections provided at a private impotence clinic for the treatment of impotence. An investigation to find additional cases revealed an outbreak requiring nationwide infection-control measures.

METHODS

Patient identification. The infectious diseases units at hospitals A and B serving the area where the implicated impotence clinic is located were notified about the unusual pathogen; statewide notification followed.

Received 2 July 2004; accepted 28 October 2004; electronically published 18 February 2005.

^a Present affiliation: Division of Infectious Diseases, Massachusetts General Hospital, Boston.

Reprints or correspondence: Dr. Jacob Strahilevitz, Div. of Infectious Diseases, Massachusetts General Hospital, 55 Fruit St., Boston, MA 02114-2696 (jstrahilevitz@partners.org).

Clinical Infectious Diseases 2005;40:781–6

© 2005 by the Infectious Diseases Society of America. All rights reserved. 1058-4838/2005/4006-0001\$15.00

All positive blood culture results were reviewed daily by infectious diseases physicians, and any case suspicious for infective endocarditis was further assessed. The mycology laboratories were alerted to report any identification of a fungus from a specimen of normally sterile body fluids and tissues, particularly if reminiscent of a dematiaceous fungus. We defined a patient as any person who had had an invasive disease caused by *P. curvatum* during the period of February 2002 through February 2003.

Epidemiological investigation. Samples from used and unused prefilled syringes provided to the patients and to asymptomatic clients of the impotence clinic were cultured. Multiple environmental samples from the house of patient 1 were obtained for fungal cultures, including any area where he stored the syringes and surfaces that he might have come in contact with during preparations for self-injection, including cotton balls and the container for the ethanol used to clean his penis prior to injection of the drugs. Environmental samples were obtained for cultures from all surfaces of the working area where drug compounding took place in the impotence clinic. Vials of the original compounds were not available for testing.

Laboratory methods. Environmental samples were obtained for culture with a moist cotton swab. For both patient and environmental isolates, a pure culture was performed with potato dextrose agar (PDA; Difco Laboratories), maintained at 28°C, and used for slide cultures on PDA. Conidial morphology

and ontogeny were examined microscopically after 3–10 days' incubation at 28°C. Species determination was made according to the overall microscopic and macroscopic appearance.

To culture samples of the fluid from the prefilled syringes, the entire volume of the syringe was filtered through a 0.2- μ m pore-size filter (Schleicher & Schuell). Used syringes were refilled to their entire volume with sterile saline and were then treated as the prefilled syringes. The filter was placed on Emons' modified Sabouraud glucose agar supplemented with 50 mg of chloramphenicol and 5 mg of gentamicin per liter and was incubated for a week at 35°C. Outgrowing fungi were isolated and morphologically identified [4]. Antifungal susceptibilities were assessed by the NCCLS M38-A microdilution method [5], using 100% inhibition as the end point. Serum voriconazole concentrations were measured by liquid chromatography–tandem mass spectrometry [6].

DNA sequencing of the nuclear ribosomal internal transcribed spacer (ITS) region and subsequent analysis was done using the method detailed by Proia et al. [7]. For a nucleotide gap encountered in 9 strains of sequence type 4 (table 1), an additional code was introduced. All other gaps were treated as missing characters.

Several environmental and patient isolates were deposited in the culture collection of the CBS Fungal Biodiversity Center (Utrecht, The Netherlands). Accession numbers are shown in table 1.

Table 1. Isolates studied and their origin, substrate, and GenBank accession numbers.

<i>Phialemonium curvatum</i> sequence type, strain number(s)	Geographic origin	Source of isolation (site)	Variable nucleotides at key alignment positions in ITS			
			65	83	84	456
Type 1: 102172 ^a and 102173 ^a	Brazil	Human (blood)	C	A	C	T
Type 2						
832.71 ^{a,b}	Argentina	Human (keratitis)	C	A	C	C
111236 ^a	The Netherlands	Dialysis fluid	C	A	C	C
489.82 ^a	Ohio	Human (keratitis)	C	A	C	C
113274 ^a	Germany	Human (keratitis)	C	A	C	C
Type 3: Isr 1, Isr 4, 110572, ^a and 113965–7 ^a	Israel	Human (blood, heart valve, and vertebral mass) and unused syringe	C	A	T	C
Type 4						
491.82 ^{a,c}	California	Soil from chaparral	T	—	T	C
490.82 ^{a,d}	Georgia	Human (skin lesion)	T	—	T	C
492.82 ^{a,c}	Colorado	River water	T	—	T	C
110659 ^{a,e}	Chicago	Human (blood, catheter site, and heart valve)	T	—	T	C

NOTE. A, adenosine; C, cytosine; ITS, internal transcribed spacer; T, thymidine; —, gap in alignment.

^a Centraalbureau voor Schimmelcultures (Utrecht, The Netherlands) culture collection number.

^b Previously identified as *Volutella cinerescens*.

^c Previously identified as *Phialemonium dimorphosporum*.

^d Ex-type strain of *P. curvatum*.

^e Also includes 5 identical outbreak isolates [7].

RESULTS

Three patients with *P. curvatum* invasive disease were identified. All 3 patients had endocarditis.

Case Reports

Patient 1. An 84-year-old man was admitted to hospital A in February 2002 for new-onset lower-back pain and deteriorating renal function. Medical history included aortic valve replacement with a biological prosthesis because of aortic stenosis (which had been performed 4 years earlier), hypertension, and chronic renal failure (creatinine level, 2.0 mg/dL). At hospital admission, the patient was afebrile. Physical examination was remarkable for bitemporal atrophy, systolic murmur of 3/6 over the aortic area, and pain to percussion over the lumbar spine. There were no peripheral stigmata of infective endocarditis. The erythrocyte sedimentation rate (ESR) was 90 mm/h (Westergren), and the creatinine level was 3.5 mg/dL. Urinalysis revealed microhematuria. Blood cultures were sterile. Radiological studies of the spine showed bulging of the disk between vertebrae L4 and L5 and narrowing of the spinal cord canal, destruction of the end plates, lysis of the L4 and L5 vertebral bodies, and thickening of the paravertebral tissue—which is compatible with osteomyelitis. Examination of biopsy material from L5 disclosed chronic inflammation, but no pathogens were seen on microscopy. Bone culture grew a single colony of a mold initially identified as *Acremonium kiliense*, which was considered to be a contaminant. The first transesophageal echocardiography disclosed a 17-mm long immobile mass of inhomogenous appearance attached to the strut of the bioprosthetic valve near the right coronary sinus compatible with a partially calcified thrombus. The valve cusps showed normal thickness and motion.

The patient was treated with vancomycin for presumed bacterial spinal osteomyelitis and endocarditis. One month after hospital admission, while still afebrile, the patient developed acute sensory aphasia. CT of the brain revealed an ischemic stroke in the territory of the left middle cerebral artery, suggestive of embolic origin. Four of 5 blood culture sets grew the same mold that grew in the bone culture, later identified as *P. curvatum*. Repeated transesophageal echocardiography showed the same mass attached to the prosthetic strut and an additional mobile mass (diameter, 6 mm) attached to the prosthetic aortic leaflet, with mild to moderate aortic regurgitation. Treatment with amphotericin B colloidal dispersion (Amphocil [Sequus Pharmaceuticals Gameda-Mediquip]; 5 mg/kg q.d.) was started, but while retching, the patient lapsed into a coma. CT of the brain showed multiple hemorrhagic infarcts. The patient died shortly thereafter.

Because the source of infection was unclear, a thorough questioning of the patient's spouse was performed, which revealed that the patient had experienced recent impotence. He self-

injected solution that contained papaverine into his penile corpus cavernosus with prefilled syringes provided by an impotence clinic. A physical examination conducted shortly before he died revealed multiple injection marks on his penile shaft, without signs of local infection.

Patient 2. A man aged 55 years was admitted to hospital A in September 2002 with a 6-month history of joint pain and a recent onset of fever. The prominent findings of a physical examination were a temperature of 38.2°C, a 3/6 systolic murmur over the left sternal border, and inflamed right ankle and left knee joints. Transesophageal echocardiography revealed a vegetation (diameter, 15 mm) on the aortic valve. CT disclosed splenic lesions consistent with infarcts or abscesses. Four of 5 blood cultures yielded *P. curvatum*. Blood culture results remained negative thereafter. The patient underwent urgent aortic valve replacement and splenectomy. Cultures of specimens from the valve were positive for *P. curvatum*. Treatment was initiated with amphotericin B (1.5 mg/kg q.d.) for 3 weeks, followed by voriconazole (400 mg q.d.).

Shortly after voriconazole therapy had been started, the patient experienced new-onset right knee arthritis. A joint fluid culture was positive for *P. curvatum*. The voriconazole dosage was increased to 800 mg per day, and the patient's clinical condition improved. However, at follow-up, increases in the alanine aminotransferase level (to 800 U/L) and γ -glutamyltransferase level (to 400 U/L) forced a reduction in the daily dose of voriconazole to 400 mg. The patient's peak serum voriconazole concentration was 0.97 mg/L, and the trough level was 0.31 mg/L. The MIC of voriconazole was 0.5 mg/L. After 5 months of therapy, the patient complained again of increasing back pain. Spinal CT and MRI and bone scan did not yield any significant findings, and the patient's ESR was 100 mm/h. Blood cultures remained sterile. A biopsy revealed active osteomyelitis; no fungi were seen in stained biopsy material, and bone culture results remained negative. The patient's therapy was switched to oral posaconazole (400 mg b.i.d.; MIC, 1 mg/L). Over a 3-month period, his backache improved, and the ESR decreased to 80 mm/h.

The patient had been performing intracavernous penile injection with prefilled syringes provided by the same impotence clinic. He kept the syringes in his car.

Patient 3. A 71-year-old man was admitted to hospital B in December 2002 with chest pains. Medical history included aortic valve replacement with a biological prosthesis and coronary artery bypass grafting, both performed in 1988, as well as hypertension. Physical examination disclosed systolic aortic murmur and a tender soft-tissue mass in the first interdigital space of the right hand. On the third day of hospitalization, the patient complained of visual disturbances, and he was found to have a fever. Ophthalmologic examination was nonrevealing. Blood culture results became positive for *P. curvatum* 7 days

later (day 10 of hospitalization). Transesophageal echocardiography revealed a large vegetation on the aortic valve, and the patient underwent valve replacement. Because of renal failure, the initial antifungal treatment with amphotericin B was switched to voriconazole (600 mg q.d.). Repeated eye ground examinations revealed severe bilateral endophthalmitis. The patient underwent bilateral vitrectomy. Septate hyphal elements were seen on a direct stain of vitreous fluid. Voriconazole treatment was continued at a daily dose of 400 mg for a total duration of 3 months. The patient fully recovered but remains blind. Being aware of the previous cases at hospital A, the physicians inquired about penile injections. The patient disclosed that he had performed intracavernous penile injections using prefilled syringes obtained from the same impotence clinic.

Epidemiological Investigation

In the residence of patient 1, a total of 3 used syringes were found in the medicine cabinet, and 2 closed envelopes containing 5 unused syringes were found in a designated drawer in the refrigerator. Cultures of samples from all used syringes and from 4 of the 5 unused syringes yielded *P. curvatum*. Cultures of environmental samples from the shelves where the syringes were kept, as well as from the closed envelope within which the syringes were provided, were negative for the mold. Patient 3 provided an unused prefilled syringe that he kept at home. Culture of the syringe fluid yielded the same mold. The same impotence clinic provided the prefilled syringes to all 3 patients. An additional investigation revealed that the prefilled syringes were prepared on a working surface in the clinic by the physicians who treated the patients. This violated the Pharmacist Ordinance in Israel, which allows only certified pharmacists in pharmacy premises to prepare and dispense medications. Each syringe was filled with a mixture that consisted

of separate stock solutions of atropine, prostaglandin E1, phenolamine, and papaverine. The stock solutions were ordered from a pharmacist. The mixing of the solutions was tailored to meet unique patient requirements and was done on a working surface in an examination room in the clinic. Cultures of environmental samples from this room and the other parts of the clinic did not yield *P. curvatum*.

Actions Taken

The Ministry of Health announced a nationwide alert recall of all medications provided by the impotence clinic. Seven clients returned prefilled syringes and 5 unused bottles (containing compounded drugs provided by the clinic so that clients could prepare syringes themselves). Of these items, samples from 2 syringes and 2 bottles grew *P. curvatum* on culture. Culture of samples from another bottle yielded the fungal opportunistic pathogen *Paecilomyces lilacinus*, and cultures of samples from 2 different syringes provided by 1 client grew *P. curvatum* in one case and *P. lilacinus* in the other. The rest of the samples were culture negative. Because this outbreak is currently under criminal investigation, no additional information is available. The Ministry of Health instructed the managers of the clinic to stop preparing and dispensing injections in its offices and to supply the patients with prescriptions with which medications could be obtained from a certified pharmacy.

Fungal Identification and Relatedness Testing

The isolates obtained were classified as members of the *P. curvatum* complex. They were morphologically indistinguishable from strains involved in a recent dialysis-related outbreak in Chicago, Illinois [7]. Both sets of strains formed structures classically associated with *P. curvatum*, such as cream-colored

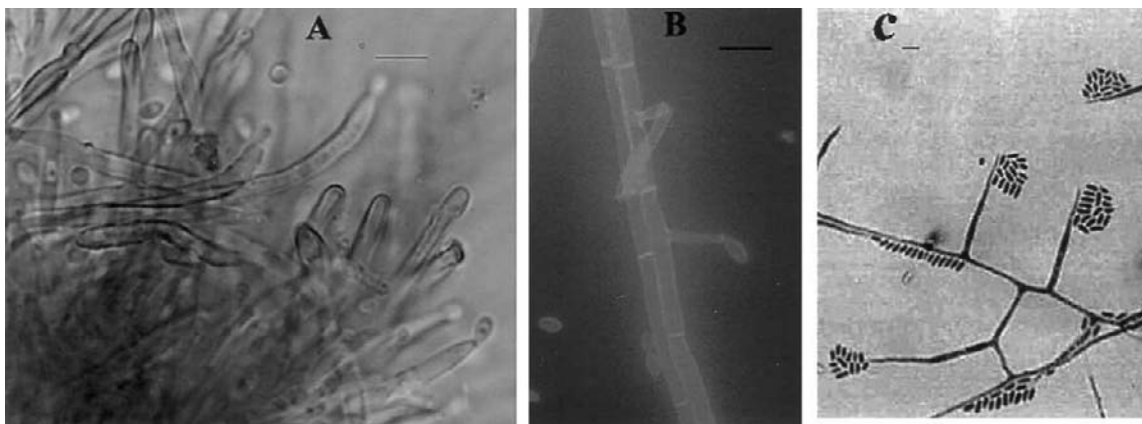


Figure 1. Microscopic morphology of strains from an outbreak of *Phialemonium curvatum* infective endocarditis. Distinctive features of outbreak strains shown are setose and cupulate sporodochium, showing conidium formation from branched conidiophores (A); conidium produced on typical tapering adelophialide lacking a basal septum (B); and hyphae with lateral and intercalary phialidic conidiogenous cells, with typical clusters of conidia aggregating in slimy heads (C). Scale bars = 10 μ m.

to yellow- or yellow-grey-colored colonies that grow to 25–30 mm in diameter after 14 days on Sabouraud agar at 25°C; short, basally aseptate phialides (adelophialides) in addition to basally septate, conventional phialides (figure 1); and ellipsoidal to gently curved, 1-celled conidia (4–5 $\mu\text{m} \times 2\text{--}3 \mu\text{m}$ in size). In addition, the 2 sets of outbreak strains both differed from previously described *P. curvatum* strains because they formed prominent, cupulate sporodochia (figure 1A) [7] up to 1.5 mm across and 1.5 mm high, with an exterior consisting of golden-brown-colored, stiff, setose hairs and an interior consisting of a densely packed mass of branching phialoconidiophores giving rise to masses of yellow, mucoid conidia. These strains have been described in greater detail in connection with the previous outbreak report [7].

A comparison of ITS sequences (table 1) of outbreak strains was done, along with comparisons with those of reference *P. curvatum* complex strains and those of strains from other outbreaks and individual cases. Sequence lengths of 466–468 bp were obtained. The 6 sequenced isolates from the current outbreak shared a unique ITS genotype, consistently distinguished at either 1 or 2 parsimony-informative positions from all isolates known from other sources (table 1). A parsimony analysis was done on 96 parsimony-informative characters (data not shown), most of which involved differences with 3 outgroup sequences (*Phialophora fastigiata* [GenBank accession number AF08319], *Phialophora lignicola* [AF083193], and *Coniochaeta ligniaria* [AY198390]). Only 4 parsimony-informative characters differed within the *P. curvatum* isolates studied (table 1). Not surprisingly, given the small number of base-pair differences seen in *P. curvatum*, no strongly supported clades were generated; thus, a dendrogram is not shown. However, sequence type 4, which is known only from the United States and which was involved in the dialysis-related outbreak of infection mentioned above, was moderately well supported, with an 83% bootstrap value.

To further test the uniformity of the outbreak isolates, we also sequenced the actin locus intron and exons for a subset of the strains examined. We again found that the outbreak strains were identical, and they were consistently distinguished from all isolates from other sources (data not shown).

DISCUSSION

That prefilled unused and used syringes were all contaminated with *P. curvatum* with a novel genotype, which was otherwise only known from the associated endocarditis cases, indicates that the common vector of infection in this outbreak was the ready-made intrapenile syringes used for self-administration. To our knowledge, this mode of infection has not yet been described elsewhere.

Intracavernous injection for the treatment of impotence is regarded as a safe procedure [8–10]. Infectious complications

have very rarely been reported and have included purulent cavernitis [11] and, in a single patient with diabetes mellitus, staphylococcal bacteremia [12]. Although our patients had repeatedly injected contaminated medications into their penile corpus cavernosus, they had no signs of local infection. This might be because intrapenile papaverine administration requires careful intravascular injection of the drugs, causing local vasodilatation, thereby carrying the pathogen rapidly into the systemic circulation, causing systemic but not local infection [13].

A distinctive feature of our patients is that, unlike most patients with fungal endocarditis, all had positive blood culture results [14, 15]. *Phialemonium* infections emerge as second only to *Fusarium* infections in the ease by which the filamentous fungus is isolated from blood samples obtained from patients with primary fungemia or endocarditis [3, 16, 17]. In addition, recently, members of the genetically diverse [16] *P. curvatum* species complex have caused a nosocomial outbreak of infection among 4 hemodialysis patients in the Chicago area, 3 of whom had positive blood culture results [7].

Fungal endocarditis is uncommon and is usually associated with known predisposing factors [14, 15]. Late postoperative endocarditis, as well as native-valve fungal endocarditis, in non-injection drug users is usually associated with severe immunocompromised states, which enable hematogeneous seeding of the fungus from an infected focus [18–20]. There are few case reports of late postoperative mold endocarditis for which no risk factor was identified [19, 21–23]. Our patients' presentation was puzzling at first, because the endocarditis had occurred 4 years after cardiac valve operations in patients 1 and 3, and no other risk factor for recent fungemia could initially be identified for any of the patients. The 3 cases described here support the hypothesis that the pathogenesis of late postoperative mold endocarditis involves direct intravascular seeding of a large inoculum of the pathogen.

The present report documents an unprecedented outbreak of invasive systemic mycosis caused by *P. curvatum* with a unique genotype among Israeli customers of an impotence clinic. The linkage between the cases and epidemiologically related environmental isolates in this outbreak is documented by the presence of a distinctive signature sequence in the variable ribosomal ITS region in all isolates. In addition, all outbreak-related isolates had in common the distinctive morphological character of sporodochium formation. A limitation of this study is the lack of a definitive original source of contamination. This may owe, in part, to the restrictions on data availability imposed by the ongoing criminal investigation, although, ultimately, even the most dogged diligence in searching for the environmental origins of common-source outbreaks is only occasionally rewarded [24, 25]. Intracavernous penile injections should be recognized as a risk factor for life-threatening fungemia. As the medical treatment of erectile dysfunction becomes more socially acceptable, physicians

should consider this exposure, which is often not volunteered by the patient [26], when hunting for a source of cryptic bloodstream infection. This outbreak also underscores the reality that pharmaceutical compounds should be prepared by persons with appropriate medication-compounding training and that compounding guidelines need to be strictly enforced.

Acknowledgments

Potential conflicts of interest. All authors: no conflicts.

References

1. Feldman HA, Goldstein I, Hatzichristou DG, Krane RJ, McKinlay JB. Impotence and its medical and psychosocial correlates: results of the Massachusetts Male Aging Study. *J Urol* **1994**; *151*:54–61.
2. Shabsigh R, Padma-Nathan H, Gittleman M, McMurray J, Kaufman J, Goldstein I. Intracavernous alprostadil alphadex (Edex/Viridal) is effective and safe in patients with erectile dysfunction after failing sildenafil (Viagra). *Urology* **2000**; *55*:477–80.
3. Gavin PJ, Sutton DA, Katz BZ. Fatal endocarditis in a neonate caused by the dematiaceous fungus *Phialemonium obovatum*: case report and review of the literature. *J Clin Microbiol* **2002**; *40*:2207–2212.
4. de Hoog GS, Guarro J, Gené J, Figueras MJ. Atlas of clinical fungi. 2nd ed. Utrecht, The Netherlands: Centraalbureau voor Schimmelcultures, **2000**.
5. NCCLS. Reference method for broth dilution antifungal susceptibility testing of filamentous fungi; approved standard. Document M38-A. Wayne, PA: NCCLS, **2002**.
6. Keevil BG, Newman S, Lockhart S, Moore CB, Howard SJ, Denning DW. Validation of an assay for voriconazole in serum samples using liquid chromatography-tandem mass spectrometry. *Ther Drug Monit* **2004**; *26*:650–7.
7. Proia LA, Hayden MK, Kammeyer PL, et al. *Phialemonium*, an emerging mold pathogen causing 4 cases of hemodialysis-associated endovascular infection. *Clin Infect Dis* **2004**; *39*:373–9.
8. Kapoor VK, Chahal AS, Jyoti SP, Mundkur YJ, Kotwal SV, Mehta VK. Intracavernous papaverine for impotence in spinal cord injured patients. *Paraplegia* **1993**; *31*:675–7.
9. Lakin MM, Montague DK, VanderBrug Medendorp S, Tesar L, Schover LR. Intracavernous injection therapy: analysis of results and complications. *J Urol* **1990**; *143*:1138–41.
10. Girdley FM, Bruskevitz RC, Feyzi J, Graversen PH, Gasser TC. Intracavernous self-injection for impotence: a long-term therapeutic option? Experience in 78 patients. *J Urol* **1988**; *140*:972–4.
11. Schwarzer JU, Hofmann R, Leyh H. Purulent cavernitis as a complication of self injection into the cavernous body [in German]. *Urologe A* **1991**; *30*:70–1.
12. Parfitt VJ, Wong R, Dobbie A, Hartog M, Gingell JC. Staphylococcal septicaemia complicating intracavernosal autoinjection therapy for impotence in a man with diabetes. *Diabet Med* **1992**; *9*:947–9.
13. Murphy EL, DeVita D, Liu H, et al. Risk factors for skin and soft-tissue abscesses among injection drug users: a case-control study. *Clin Infect Dis* **2001**; *33*:35–40.
14. Ellis ME, Al-Abdely H, Sandridge A, Greer W, Ventura W. Fungal endocarditis: evidence in the world literature, 1965–1995. *Clin Infect Dis* **2001**; *32*:50–62.
15. Pierrotti LC, Baddour LM. Fungal endocarditis, 1995–2000. *Chest* **2002**; *122*:302–10.
16. Guarro J, Nucci M, Akiti T, et al. *Phialemonium* fungemia: two documented nosocomial cases. *J Clin Microbiol* **1999**; *37*:2493–7.
17. Schonheyder HC, Jensen HE, Gams W, et al. Late bioprosthetic valve endocarditis caused by *Phialemonium* aff. *curvatum* and *Streptococcus sanguis*: a case report. *J Med Vet Mycol* **1996**; *34*:209–14.
18. Rubinstein E, Noriega ER, Simberkoff MS, Holzman R, Rahal JJ Jr. Fungal endocarditis: analysis of 24 cases and review of the literature. *Medicine (Baltimore)* **1975**; *54*:331–4.
19. Gumbo T, Taeye AJ, Mawhorter S, et al. *Aspergillus* valve endocarditis in patients without prior cardiac surgery. *Medicine (Baltimore)* **2000**; *79*:261–8.
20. Revankar SG, Patterson JE, Sutton DA, Pullen R, Rinaldi MG. Disseminated phaeohyphomycosis: review of an emerging mycosis. *Clin Infect Dis* **2002**; *34*:467–76.
21. Camin AM, Michelet C, Langanay T, et al. Endocarditis due to *Fusarium dimerum* four years after coronary artery bypass grafting. *Clin Infect Dis* **1999**; *28*:150.
22. Khan ZU, Sanyal SC, Mokaddas E, et al. Endocarditis due to *Aspergillus flavus*. *Mycoses* **1997**; *40*:213–7.
23. Roux JP, Koussa A, Cajot MA, et al. Primary *Aspergillus* endocarditis: apropos of a case and review of the international literature [in French]. *Ann Chir* **1992**; *46*:110–5.
24. Centers for Disease Control and Prevention. *Exophiala* infection from contaminated injectable steroids prepared by a compounding pharmacy—United States, July–November 2002. *MMWR Morb Mortal Wkly Rep* **2002**; *51*:1109–12.
25. Selenic D, Dodson DR, Jensen B, Arduino MJ, Panlilio A, Archibald LK. *Enterobacter cloacae* bloodstream infections in pediatric patients traced to a hospital pharmacy. *Am J Health Syst Pharm* **2003**; *60*:1440–6.
26. Chun J, Carson CC 3rd. Physician-patient dialogue and clinical evaluation of erectile dysfunction. *Urol Clin North Am* **2001**; *28*:249–58.